

Computed Tomography–Based Exploration of Infundibular Anatomy for Maxillary Sinus Balloon Dilation

Ashley Sikand, MD

Objectives: A clinically relevant reconstruction of the ethmoid infundibulum and maxillary sinus ostium was developed to use 3-dimensional computed tomographic (CT) imaging technology and measurement software in an effort to better understand the anatomy of the maxillary sinus ostium and to optimize the maxillary sinus balloon dilation technique.

Methods: A retrospective review was performed of reconstructed high-resolution CT scans of patients from a private otolaryngology practice who underwent imaging for evaluation of sinus disease using multiplanar reconstruction software. The CT scans were retrospectively obtained from patients who presented for evaluation of chronic sinus disease and were analyzed with quantitative multiplanar reconstruction software that allowed measurements to be computed in clinically meaningful planes.

Results: Data were obtained from 31 sinuses on 18 CT scans. The mean anteroposterior distance from the guidewire exit to the maxillary ostium was 3.5 mm, and the mean optimal guide trajectory (“clocking”) angle was 17.5° from the pure axial plane (95% confidence interval, 12.58° to 22.48°). The curvilinear guidewire travel distance was 6.9 mm from the guidewire exit to the ostial entry.

Conclusions: This study reveals specific anatomic information that is applicable to the technique of transnasal maxillary sinus balloon catheter dilation. The data collected allow surgeons to anticipate the direction in which a guidewire must be manipulated in order to correctly enter the maxillary ostium. According to the data, a gentle anterior retraction of the uncinate process and a starting guide orientation 18° from pure lateral will best facilitate maxillary sinus ostial access. Application of the readily available software used for this study affords the opportunity to predict the location of the natural ostium within the infundibulum before operation and customize the technique to each specific patient.

Key Words: computed tomography of sinus, sinus balloon dilation, sinus surgery.

INTRODUCTION

Balloon catheter dilation of the paranasal sinuses offers a unique opportunity to re-establish maxillary sinus ostial drainage without removing the uncinate process. Although the literature suggests a high success rate in gaining access to the maxillary sinus with a sinus guidewire,¹ navigating the ethmoid infundibulum with a guidewire and successfully traversing the maxillary sinus ostium while retaining the uncinate process can be challenging in certain cases.

Although guidewires placed through guides (Relieva Flex sinus guide catheter and Relieva Vigor sinus guidewire, Acclarent, Inc, Menlo Park, California) used to access the maxillary sinus ostium are soft, pliable instruments capable of precisely traversing the maxillary canal or ostium,² anatomic variation can result in challenging access, assuming an intact uncinate process. Ostia that are located anteriorly can be more difficult to access with a guidewire. Additionally, an ostium that is located superi-

orly within the infundibulum presents a challenge for access with a guidewire because of the close proximity of the anterior attachment of the uncinate process. Furthermore, a laterally displaced uncinate process may narrow the outflow tract and make access to the maxillary sinus ostium difficult.

This study utilized a computed tomographic (CT) software program that permits a 3-dimensional (3-D) preoperative assessment of the sinuses. The CT assessment results in calculation of specific clinically relevant dimensions and angles in an attempt to define an “ideal” guidewire trajectory for balloon catheter dilation of the maxillary sinus. The surgeon can then use the measurements to modify the surgical technique to permit more facile and successful access to the maxillary sinus ostium.

METHODS

Axial CT scans were selected retrospectively at random from a database of patients who presented to a single private practice for evaluation of sinus

Dr Sikand is a consultant for, and has received honoraria from, Acclarent Inc.

Correspondence: Ashley Sikand, MD, 8530 W Sunset Rd, Suite 230, Las Vegas, NV 89113.

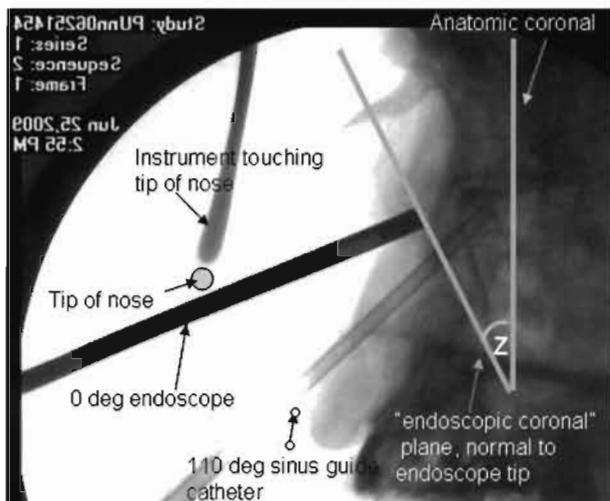


Fig 1. Fluoroscopic image of typical 0° endoscopic approach to maxillary sinus. Plane normal to tip of endoscope (“endoscopic coronal”) differs from pure anatomic coronal plane by angle z.

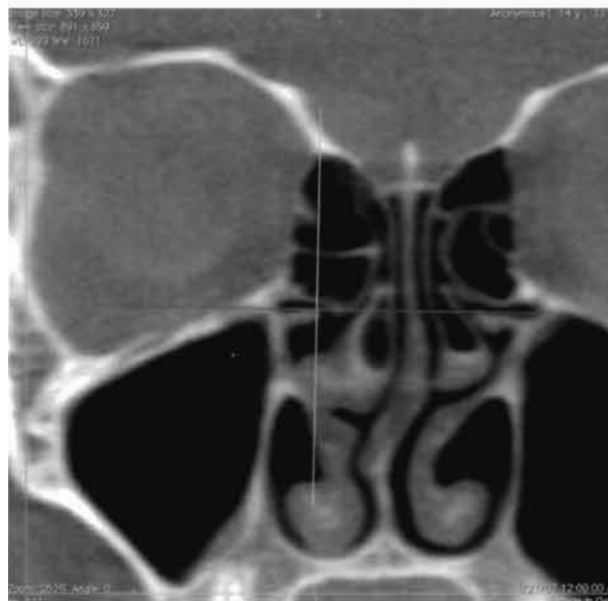


Fig 3. Crosshairs are placed between posterior-inferior border of uncinate process and anterior face of ethmoid bulla, typical location for initial sinus guide positioning.

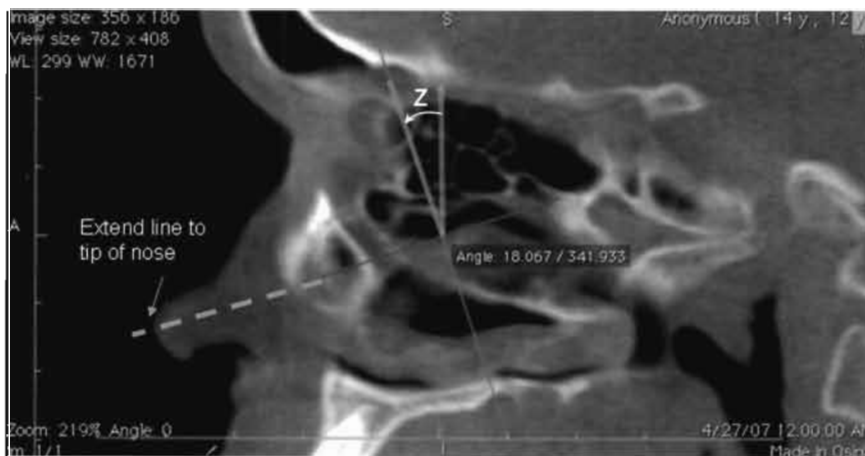
disease. The scans were obtained with a MiniCAT CT scanner (Xoran Technologies, Ann Arbor, Michigan) with a 0.4-mm slice thickness. All scans were included in the study except those that met the following exclusion criteria, which were applied to the CT scans on a per-sinus basis: evidence of prior sinus surgery, infundibular disease that obscured the anatomic areas of interest, infundibular anatomy that could not be captured in a single cross-sectional plane, maxillary sinuses without radiologic evidence of a natural ostium (pure accessory ostium drainage), or pediatric anatomy. The scans were then imported into OsiriX (v3.5.1, 64-bit) to perform multiplanar reconstruction and quantitative measurements. (OsiriX is an open-source and freely available software package for the Apple platform, available at www.osirix-viewer.com. Online instruction is available at the download site.) An Apple MacPro workstation was utilized for the analysis. A written exemption was obtained from the Western Institutional Review Board, as the research involved study

of existing data from which subjects could not be identified.

Orthogonal planes were reconstructed from the primary axial scans and manipulated with 3-D multiplanar reconstruction (MPR) tools. MPR analysis allows the standard orthogonal planes (axial, coronal, and sagittal) to be rotated and translated into any arbitrary position within the CT volume. This is critical for accurate analysis of the infundibulum, which cannot be easily visualized or accurately quantified in any one of the standard anatomic planes. The three orthogonal planes are shown in separate windows with crosshairs showing the relevant axes. Axes in any window can be rotated and/or translated to generate new cross-sectional areas. These newly generated planes are displayed in the other two windows.

Because the goal of the study was to provide data

Fig 2. Multiplanar reconstruction (MPR) planes are rotated such that MPR coronal plane simulates endoscopic coronal plane. This simulation is achieved by rotating MPR planes by angle z (18° for this patient). Using endoscopic coronal reference system permits easier clinical communication of results.



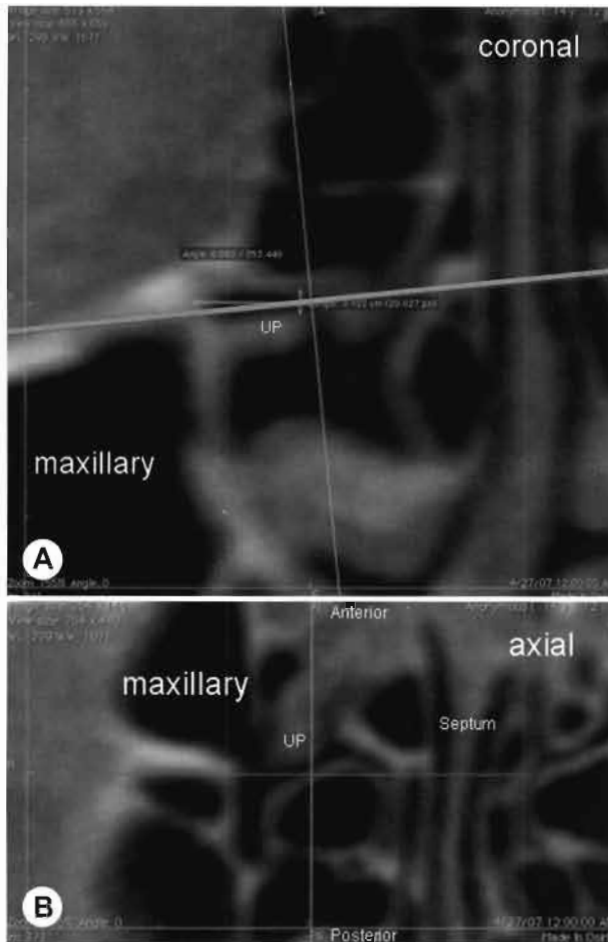


Fig 4. Adjustment of axial plane. UP — uncinat process. A) Axial plane was adjusted by rotating MPR line in coronal view. In all cases, axial plane was rotated such that lateral side of plane was moved inferiorly. “Clocking angle” is rotation required to locate plane of infundibulum. B) Axial rotation was complete when axial view demonstrated clearly defined pathway from crosshairs (simulated guidewire exit) into maxillary sinus, thus defining plane of ostial canal.

that would be easy for an operating surgeon to interpret, several manipulations of the data were accomplished. The first manipulation completed was to adjust the coronal plane to match that of a standard 0° sinuscope, creating an “endoscopic coronal” view. The endoscopic view approaching the maxillary sinus is not a pure coronal projection, as the operating surgeon must introduce the endoscope while navigating within the confines of the nasal anatomy. Figure 1 is a fluoroscopic image demonstrating the relevant angles for a typical endoscopic approach to the maxillary sinus. The angle z represents the difference between the pure anatomic coronal plane and the endoscopic coronal plane. The MPR orthogonal planes were therefore adjusted into the endoscopic coronal reference frame by tilting the coronal plane for each CT image (superior part anteriorly, inferior part posteriorly). This was performed by estimating

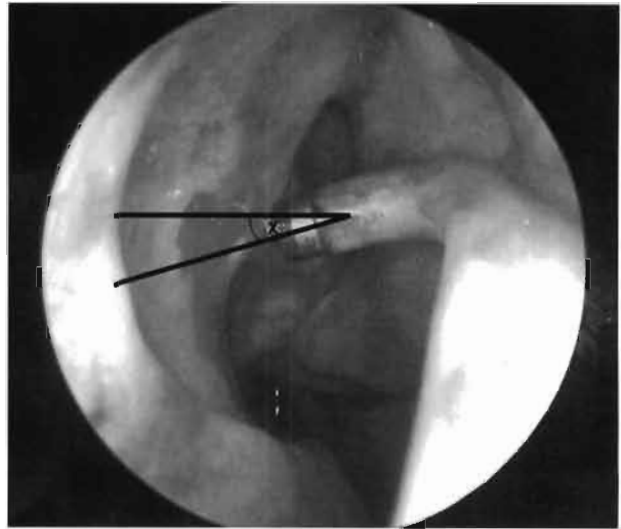



Fig 5. Clocking angle can be interpreted clinically as angle of rotation of sinus guide catheter in infundibulum, relative to pure lateral orientation (angle x). This is optimal angle to orient sinus guide into plane of infundibulum.

the endoscope location in approaching the maxillary sinus (Fig 2). Once the endoscopic coronal adjustment is made, results can be reported in a reference frame familiar to the surgeon. The term anterior now refers to the direction that *appears purely anterior* when viewed with an endoscope. In the traditional anatomic reference frames, this direction would be more accurately described as anteroinferior.

The intersection of the MPR planes was then placed in the location that approximated the exit of the sinus guidewire from the sinus guide. This location was defined as the space between the bulla and the uncinat process, at the junction between the horizontal and vertical components of the uncinat process (Fig 3).

The infundibulum will travel laterally, and may also exhibit inferior and anterior trajectories. The goal of the next MPR adjustment was to locate the axial plane that best captured a cross section of the infundibulum, demonstrating the guidewire pathway into the maxillary sinus. This was performed by tilting the lateral side of the MPR axial plane inferiorly or superiorly (Fig 4A) until the full infundibular path was visible on the resulting axial plane (Fig 4B). We propose the term “clocking angle” to describe this adjustment, which simulates the angle that the sinus guide is rotated once placed behind the uncinat process to provide the best trajectory of the sinus guidewire into the infundibulum (Fig 5). This angle can be easily communicated relative to the numbers on a clock (eg, rotation of the guide to 7 o’clock), hence the proposed term “clocking angle.” The maxillary ostium was defined as the location at the lateral ex-

Fig 6. Final double-oblique analysis plane (asterisk) is axial section that has been adjusted for endoscopic coronal reference plane (coronal tilt) and also to transect axis of infundibulum (lateral tilt).



tent of the infundibulum that demonstrated a clear opening into the maxillary sinus proper.

Figure 6 is a 3-D representation of a typical final double-oblique analysis plane, which can be customized for each patient's anatomy.

Once the infundibular analysis plane is defined, the following measurements were obtained: the anteroposterior (AP) distance between the uncinat process and the ethmoid bulla face (ie, the space within which the tip of the sinus guide would be positioned); the AP distance between the exit of the sinus guidewire and the opening of the maxillary ostium (Fig 7); and the curvilinear distance that the sinus guidewire would have to travel upon exiting the sinus guide to gain entrance into the maxillary ostium.

RESULTS

A total of 31 sinuses were included in the analysis. Twenty-one sinuses were excluded from the analysis as per the exclusion criteria. Ten sinuses showed evidence of previous sinus surgery, 8 si-

nuses contained infundibular disease that interfered with the ability to perform quantitative analysis, 2 sinuses had infundibular anatomy that could not be captured in a single plane (multiple curves), and 1 sinus appeared to drain entirely through an accessory ostium.

The average adjustment required to shift to the "endoscopic coronal" plane was 13.8° (SD, 5.1°). The average distance between the ethmoid bulla and the uncinat process was 1.5 mm (SD, 0.7 mm). The angle of declination required for the sinus guide to optimally orient the sinus guidewire toward the ostium was next measured. This "clocking angle" represents an inferior tilt of the guidewire to reach the medial extent of the ostial canal. The mean clocking angle was a 17.5° (SD, 13.5°) tilt from a pure lateral trajectory. The distribution of clocking angles required to optimally target the ostium is shown in Fig 8. The distribution was fairly uniform, such that 55% of clocking angles were greater than 17.5° and 45% were less than 17.5° . Clinically, a surgeon would rotate the guide catheter clockwise for the left

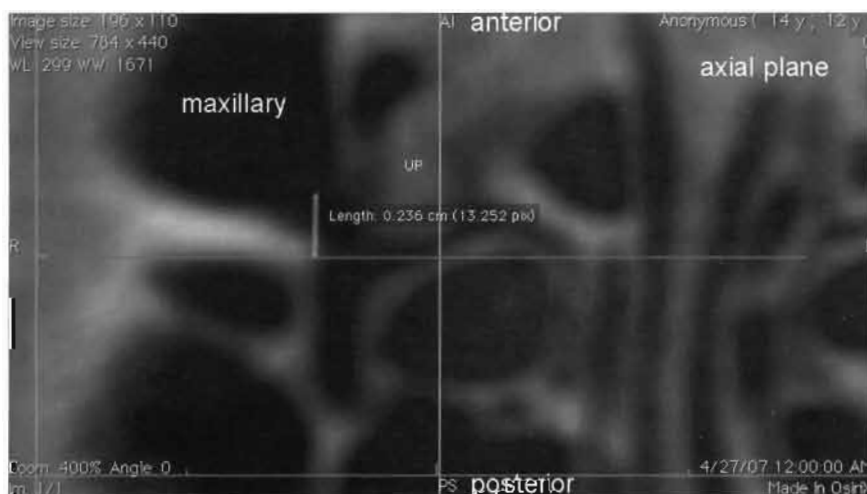


Fig 7. Anterior distance from sinus guidewire exit (axis intersection) to maxillary ostium is shown. In this patient, guidewire would have to travel 2.4 mm anteriorly (endoscopic reference plane). UP — uncinat process.

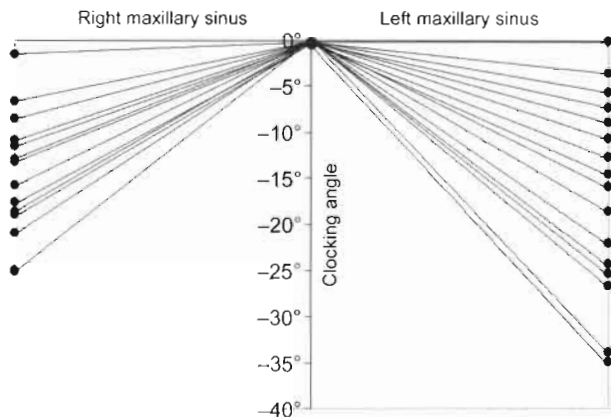


Fig 8. Clocking angle necessary to orient sinus guide into plane of ostial canal is shown for each sinus. For right maxillary sinus, guide must be rotated counterclockwise. For left maxillary sinus, guide is rotated clockwise. One data point of 73° is not shown.

sinus and counterclockwise for the right sinus in order to place the guidewire into the ostium.

The mean AP distance from the sinus guide exit to the maxillary ostium was 3.5 mm (SD, 1.8 mm). Almost half of the ostia were located between 2 and 4 mm anterior from the guidewire exit point. Nine of the 31 ostial locations were quite anterior within the infundibulum, requiring the guidewire to traverse a distance of between 4 and 8.4 mm. Finally, 7 ostia were located less than 2 mm anterior of the guidewire exit. Figure 7 gives an example measurement.

The curvilinear guidewire travel distance averaged 6.9 mm (SD, 2.3 mm). This represents the total guidewire exposed beyond the tip of the guide catheter up to the entry into the maxillary sinus.

DISCUSSION

A review of the literature describing the anatomy of the ethmoid infundibulum provides insight into the variety of locations of the maxillary sinus ostia in both the axial and coronal planes. Van Alyea³ analyzed 163 cadaver specimens and found a varied distribution of the maxillary sinus ostium within the infundibulum. He demonstrated that in 25% of sinuses the ostium would be difficult to probe because it was buried deep in the infundibulum. Myerson⁴ described the infundibulum as becoming progressively narrower moving from posterior to anterior.

Studies also show a wide variation in the length of the canal leading to the ostium and the angle of projection. Simon⁵ reported a group of 110 ostia of which 82.7% were 3 mm or more in length (mean, 5.5 mm). This study also revealed that although this maxillary canal (now more commonly termed the infundibulum) is directed in a general way inferior and lateral, there is great variability in its angle of pro-

jection. Simon⁵ therefore concluded that the natural ostium would be difficult to precisely probe with a rigid instrument. This study confirmed the variability in infundibular anatomy and highlights the complex and curvy nature of the natural infundibulum that is not often appreciated endoscopically in clinical practice. A potential benefit of a flexible guidewire over a rigid probe is the ability to “self-navigate” this complex space while minimizing interaction with surrounding structures.

Balloon catheter dilation of sinus ostia has emerged as an effective and relatively safe technique with durable results. Kuhn et al⁶ reported an ostial patency rate of 94% at 1 year of follow-up, and Levine et al⁷ found a revision rate of 1.3% in 1,438 maxillary sinuses. Balloon catheter dilation affords an opportunity to perform functional surgery with maximal preservation of normal tissue. In the case of maxillary sinus dilation, one way to achieve this is to preserve the uncinate process. However, cannulating this ostium may be troublesome in certain situations because of the wide variation in middle meatal and infundibular anatomy.

This study sought to explore CT-imaged infundibular anatomy to gain information that would result in appropriate technique modifications to permit more facile and successful access to the maxillary sinus ostium. The results indicate that the majority of ostia (21 of 31 sinuses) are located within 4 mm anterior of the guidewire exit at the posterior edge of the uncinate process. This position should allow for relatively easy channeling of a proximate ostium with a guidewire. However, 9 of 31 ostia (29%) were situated more than 4 mm anterior within the infundibulum. In these cases, the surgeon may be required to “throw” the guidewire anteriorly for 4 to 9 mm and then angle the wire laterally and inferiorly following the clocking angle in order to enter the ostium. Consequently, this is the subset of cases that poses the most difficulty in accessing the ostium. In this situation, I have used a method that gently retracts the uncinate process medially and anteriorly to gain access to the ostium. This decreases the required AP travel of the guidewire and facilitates the subsequent step of angling the guidewire inferiorly to enter the ostium.

The clocking angles calculated also provide useful information about the extent of rotation required to place the guidewire in the correct axial plane for successful access. Based on this data set, my recommendation would be to start at a clocking angle of 17.5° from the endoscopic axial and “walk” the guidewire superiorly and inferiorly along the lateral infundibular wall from 0° to 35°. This would permit

an operator to most efficiently enter the ostium. Given these findings, cannulation of the natural ostium of the maxillary sinus should be more successful if an optimal clocking angle is chosen with gentle anterior retraction of the uncinate process.

It is also of note that the mean natural distance between the uncinate process and the ethmoid bulla space was 1.5 mm. Given that the outer diameter of a standard sinus guide is 3.4 mm, mobilization of the uncinate process will be required in many cases simply to position the tip of the sinus guide. It is critical in clinical practice that the operating surgeon not attempt to directly cannulate the infundibulum deeply with the tip of the guide catheter, as the relatively larger dimension of the guide catheter tip could create mucosal damage. The guidewire, not the guide catheter tip, is the appropriate tool to probe the infundibulum.

If there is a desire for surgeons to introduce various instruments (guidewires, forceps, irrigating catheters, etc) into the infundibulum and maxillary sinus, these will have to be designed with a smaller profile to navigate the infundibulum and ethmoid bulla and to avoid trauma to the mucosa in the area.

The main limitation of the study was the inability in some cases to precisely and unambiguously define the maxillary ostial opening. The maxillary "ostium" is sometimes not a well-defined location, but rather, a more subtle transition from the infundibular space into the maxillary sinus proper. Clinical judgment was required in some cases to define the transition point from infundibulum to ostial canal. This limitation, however, is not unique to a CT-based study. Any study of the maxillary anatomy will require some degree of clinical interpretation to define the medial boundary of the maxillary sinus.

The patients selected for study had presented to a private practice clinic for evaluation of sinus disease. However, no attempt was made to exclude CT images from patients who ultimately were found not to have sinusitis, nor was selection based on the eventual diagnosis of acute or chronic sinusitis. It should be assumed that the anatomy studied represents a mix of patients who had acute sinusitis, chronic sinusitis, or perhaps no sinus disease. Further study would be needed to attempt to determine whether patients with sinus disease have different anatomic characteristics than patients without sinusitis.

It is important to highlight that this study made use of freely accessible open-source software. As such, it is readily available to surgeons, who can perform a similar analysis on individual CT scans. This software provides the capability to locate the maxillary

ostium and allows for technique selection and modification before the actual surgery. It became evident during the study that this analysis can be performed within approximately 5 minutes once the CT scan has been loaded into the software.

The main limitations of the study result from certain estimations required during the manipulation of the MPR. First, the endoscopic coronal adjustment requires an estimate of the clinical trajectory of a 0° endoscope in performing maxillary surgery. It would be ideal to find a fixed anatomic landmark to reference this MPR adjustment, but I am unaware of any prior literature in which such landmarks are described. It should be noted, however, that the potential error introduced in the estimation of endoscopic coronal adjustments does not have a large effect on the study measurements because of the very short distance between the guidewire exit and the ostial opening.

A second source of potential error is the estimate required regarding location of the sinus guide, and therefore the guidewire exit. To the extent possible, the guide was located in the space just superior to the location at which the horizontal component of the uncinate process transitions to the vertical component. This was thought to be the location that often represents clinical practice for initial guide location and is an anatomic landmark that is repeatable from the perspective of CT analysis. Surgeons who use a more superior guide position would require a steeper clocking angle (larger deviation from pure lateral) than the one reported in this study. In some CT images, the transition from the horizontal component of the uncinate process was not well defined (but rather, a more gentle continuous curve), and thus could lead to some variability in placement.

CONCLUSIONS

Exploration of the infundibular and maxillary ostial anatomy using 3-D CT imaging for compilation of clinically relevant anatomic measurements can provide anatomic information that may aid the surgeon in performing minimally invasive sinus surgery, especially when a guidewire is used for balloon catheter dilation. The AP guidewire travel distance and the sinus guide clocking angle appear to have direct clinical application in optimizing the technique used in guidewire placement. Furthermore, the technique can be specifically tailored to each patient's ostial location as determined by the CT scan by using the steps described above. This method allows for both improved preoperative planning and targeted development of the surgical technique.

Acknowledgment: I thank Dan Harfe at Acclarent Inc for his assistance in developing the analytic techniques for the CT data.

REFERENCES

1. Bolger WE, Brown CL, Church CA, et al. Safety and outcomes of balloon catheter sinusotomy: a multicenter 24-week analysis in 115 patients. *Otolaryngol Head Neck Surg* 2007;137:10-20.
2. Bolger WE, Vaughan WC. Catheter-based dilation of the sinus ostia: initial safety and feasibility analysis in a cadaver model. *Am J Rhinol* 2006;20:290-4.
3. Van Alyea OE. The ostium maxillare. *Arch Otolaryngol* 1936;24:553-69.
4. Myerson MC. The natural orifice of the maxillary sinus. *Arch Otolaryngol* 1932;15:80-91.
5. Simon E. Anatomy of the opening of the maxillary sinus. *Arch Otolaryngol* 1939;29:640-9.
6. Kuhn FA, Church CA, Goldberg AN, et al. Balloon catheter sinusotomy: one-year follow-up — outcomes and role in functional endoscopic sinus surgery. *Otolaryngol Head Neck Surg* 2008;139:S27-S37.
7. Levine HL, Sertich AP II, Hoisington DR, Weiss RL, Pritikin J; PatiENT Registry Study Group. Multicenter registry of balloon catheter sinusotomy outcomes for 1,036 patients. *Ann Otol Rhinol Laryngol* 2008;117:263-70.



THE SOCIETY FOR EAR, NOSE AND THROAT ADVANCES IN CHILDREN (SENTAC)

The annual meeting of the Society for Ear, Nose and Throat Advances in Children (SENTAC) will take place December 1-4, 2011, in Kansas City, Missouri. For further information, visit the SENTAC website www.sentac.org.